

# Excision arthroplasty of the hip joint in dogs and cats

Clinical, radiographic, and gait analysis findings from the Department of Surgery, Veterinary Faculty of the Ludwig-Maximilians-University of Munich, Germany

W. Off; U. Matis

Department of Small Animal Surgery and Reproduction, Ludwig-Maximilians-University, Munich, Germany

## Keywords

Dog, cat, hip joint, femoral head and neck ostectomy, clinical and radiographic findings, gait analysis

## Summary

From 1978 to 1989, 132 dogs and 51 cats underwent femoral head and neck ostectomy at the Department of Veterinary Surgery, Ludwig-Maximilians University, Munich, Germany. Clinical and radiographic re-evaluations were carried out an average of four

years postoperatively in 81 (44%) of the animals, and gait analysis was also done in 17. The functional results were rated good in 38% of patients, satisfactory in 20%, and poor in 42%. However 96% of the owners were satisfied with the results. Kinetic and kinematic measurements showed that although femoral head and neck resection alleviated pain, it resulted in functional deficits in small as well as large breed dogs. These deficits were not visible during rapid movement.

was used when preservation of the joint was not feasible or practical (►Fig. 1). The most frequent indication in dogs was avascular necrosis of the femoral head caused by Legg-Calvé-Perthes disease; most patients suffering from this disease weighed <15 kg (►Fig. 2). Seventy-five percent of the patients were less than two-years-old.

A craniolateral approach to the hip was used in all cases. After reflection of the joint capsule and transection of the round ligament, the limb was rotated outwards 90°. Osteotomy of the femoral neck was achieved using an osteotome or oscillating saw. Sometimes the lesser trochanter was also resected. In order to completely remove the caudal edge of the femoral neck, the osteotome or saw was directed in a caudolateral direction (►Fig. 3) rather than perpendicular to the long axis of the femoral neck. The goal was to create a smooth resection plane with no bony protuberances. In the majority of cases, the joint capsule was closed to provide a layer of tissue between the acetabulum and cut surface of the femur after removal of the femoral head and neck (►Fig. 4) (17). An additional procedure used in some patients near the end of the study period was placement of one or two heavy, slowly-absorbable sutures to attach the gluteal tendons to the insertion of the rectus femoris muscle to prevent caudodorsal malposition of the femur. Wound closure was routine. Ventrodorsal radiographs were obtained immediately after surgery to determine the orientation of the osteotomy plane.

Follow-up examinations of 81 patients (66 dogs and 15 cats) were carried out seven months to 10 years after surgery

## Correspondence to:

Prof. Dr. Ulrike Matis  
Vorstand der Chirurgischen und Gynäkologischen  
Kleintierklinik der Ludwig-Maximilians-  
Universität München  
Lehrstuhl für Allgemeine und Spezielle Chirurgie  
einschließlich Augenkrankheiten  
Veterinärstr. 13  
80539 München  
Germany  
Phone: +49 89 2180 2628  
Fax: +49 89 39 53 41  
E-mail: matis@lmu.de

## Vet Comp Orthop Traumatol 2010; 23: 297-305

This article was originally published in 1997 in the journal *Tierärztliche Praxis*. Both authors have approved the re-publication of this article in English, for which they have provided the translation of as well. *Original citation:* Off W, Matis U. Resektionsarthroplastik des Hüftgelenkes bei Hunden und Katzen. Klinische, röntgenologische und ganganalytische Erhebungen an der Chirurgischen Tierklinik der Ludwig-Maximilians-Universität München. *Tierärztl Prax* 1997; 25: 379–387.

## Introduction

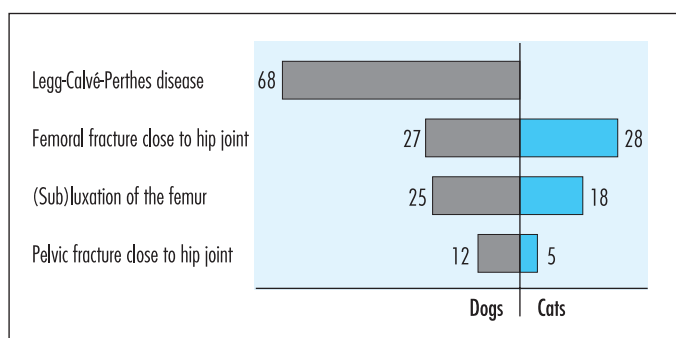
Femoral head and neck ostectomy (FHO) is a relatively straightforward procedure and has been the topic of many studies (1, 2, 4–8, 10–12, 18–24). The techniques and surgical approaches used as well as the results of the procedure vary. In some studies, the findings have been based solely on the outcome of owner questionnaires.

The aim of this study was to investigate the efficacy of FHO using the results of clinical and radiographic follow-up exami-

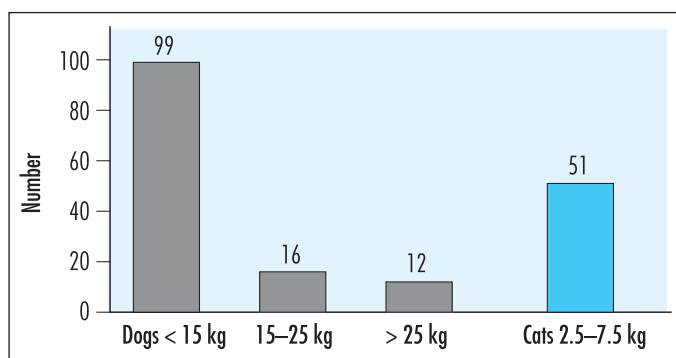
nations of patients in the Department of Veterinary Surgery, Ludwig-Maximilians-University, Munich, Germany. Kinetic and kinematic evaluations were also undertaken in some dogs because the human eye cannot fully and accurately assess quadruped motion.

## Materials and methods

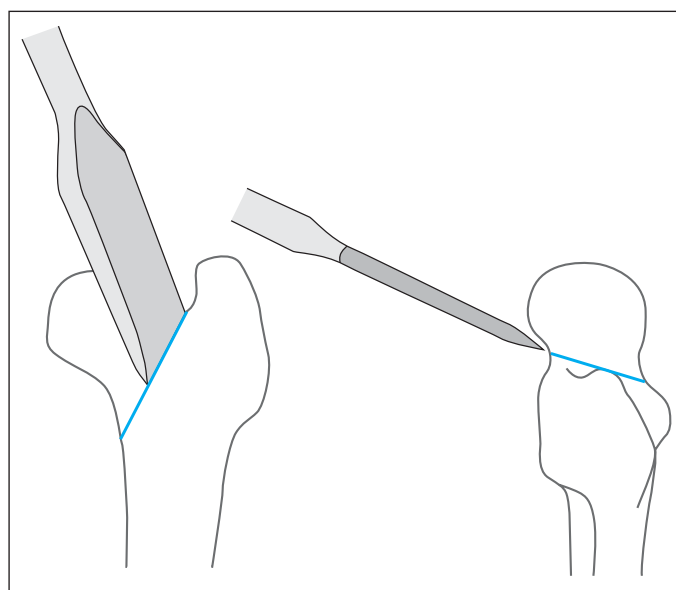
From 1978 to 1989, FHO was carried out in 132 dogs and 51 cats. The procedure



**Fig. 1** Indications for femoral head and neck osteotomy in 132 dogs and 51 cats.



**Fig. 2** Body weight distribution of 132 dogs and 51 cats that underwent femoral head and neck osteotomy (Body weight of 5 dogs unknown).



**Fig. 3** Direction of the osteotome during osteotomy of the femoral neck.

(mean 4 years) at our clinic. The clinical variables evaluated included lameness, muscle atrophy, pain with passive movement, crepitus, caudodorsal malposition of the femur, and range-of-motion. These objective variables were supplemented by the owners' evaluations of:

- Duration of preoperative signs
- Duration of postoperative convalescence
- Weight bearing on the affected limb at a slow gait, fast gait, after strenuous exercise and during cold or wet weather
- Subjective assessment of overall surgical success

The evaluations were scored as follows:

- **Good:** no lameness, complete weight bearing at all gaits.
- **Satisfactory:** slight lameness, occasional stiffness, occasional non-weight-bearing lameness.
- **Unsatisfactory:** permanent mild to severe lameness, frequent non-weight-bearing lameness, lameness after exercise, lameness at a trot and/or gallop, weather-associated lameness.

Radiographs taken immediately postoperatively were available in 67 patients (55 dogs and 12 cats) for assessment of complete resection of the femoral neck with or without removal of the lesser trochanter and the presence of sharp bony edges along the osteotomy line.

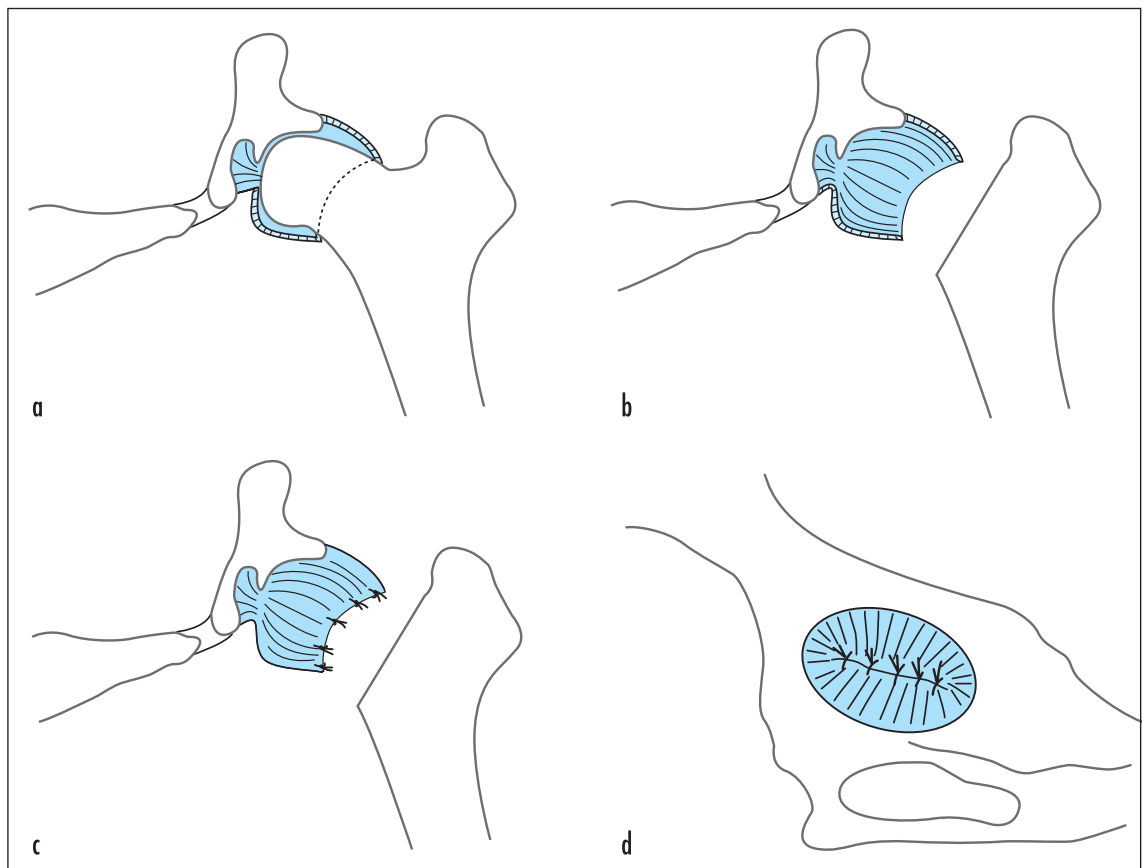
Seventeen dogs were also evaluated in the gait laboratory (18, 19). The following kinetic data were evaluated using a treadmill with four integrated force plates:

- Stance time (msec)
- Peak vertical ground reaction force (% BW)
- Slope of ground reaction curve (% BW/sec)
- Integral (% BW x sec)

Kinematic data were collected using reflective markers over the iliac crest, greater trochanter, lateral femoral condyle, fibular malleolus, and the fifth metatarsal bone to provide joint angles of the hip, stifle, and tarsal during motion.

## Results

Postoperative re-evaluation showed that 68 patients (84%) had limb shortening (caudodorsal malposition of the femur), 61 (75%) had muscle atrophy, 60 (74%) had reduced range-of-motion during extension and abduction of the hip hindlimb, 45 (56%) had signs of lameness, 26 (32%) showed signs of pain during passive movement of the limb, and eight (10%) patients had crepitus (▶ Table 1). There was a small number of dogs that weighed more than 15 kg, but this group tended to have worse results than smaller patients. Subjective evaluation indicated that cats had the fewest postoperative problems. Although

**Fig. 4**

The joint capsule was interposed between the osteotomy site and acetabulum to prevent pain from bone-to-bone contact. **a)** Transverse view through the hip joint before resection; **b)** appearance after removal of the femoral head and neck; **c)** closure of the joint capsule; and **d)** ventral view of the acetabulum after closure of the joint capsule.

clinical lameness was not detected in any of the cats, owners of five of the 15 cats reported a shortened stride after exercise, during weather changes, at a fast or slow gait, or after long periods of rest.

Based on the owners' observations, the load placed on the operated leg at a slow gait was normal in 69 patients (85%) and it remained normal at a fast gait in 52 (64%). Lameness was seen in 19 patients (23%) after strenuous exercise and in 20 patients (24%) during cold weather (► Table 2). However, 78 of 81 (96%) owners felt that the procedure had a successful outcome. The mean duration of convalescence was four to six weeks in cats and small dogs, and seven to nine weeks in dogs over 15 kg even though the duration of preoperative lameness in the latter group was on average shorter than that of smaller patients. Based on information from the client questionnaire combined with the results of clinical re-evaluations, the functional results were considered good in 38% of the patients, satisfactory

**Table 1** Clinical signs in 66 dogs and 15 cats seven months to 10 years (mean 4 years) after femoral head and neck osteotomy.

Clinical parameters	Total n = 81	Dogs			Cats n = 15
		<15 kg BW n = 51	15 - 25 kg BW n = 4	>25 kg BW n = 11	
Caudodorsal malposition of the femur	68 (84%)	41	4	10	13
Muscle atrophy	61 (75%)	39	4	11	7
Restricted range-of-motion	60 (74%)	34	4	11	11
Lameness	45 (56%)	35	1	9	-
Pain on passive movement	26 (32%)	17	1	4	4
Crepitus	8 (10%)	4	1	3	-

BW = Body weight

in 20% and unsatisfactory in 42%. There was no correlation between body weight and functional outcome (► Table 3). Preoperative signs were seen for a mean of five weeks in patients with good results

and a mean of seven weeks in patients with poorer outcomes (► Table 4).

Postoperative radiographs showed complete osteotomy of the femoral head and neck in 40 animals (60%), half of which had also

	Total n = 81	Dogs			Cats n = 15
		<15 kg BW n = 51	15 - 25 kg BW n = 4	>25 kg BW n = 11	
Mean duration of preoperative signs (P = Perthes; R = Remainder of dogs)		P = 12 weeks R = 3 weeks	0.5 weeks	3 weeks	4 weeks
Mean duration of postoperative convalescence		6 weeks	7 weeks	9 weeks	4 weeks
Normal (100%) weight-bearing on the operated limb					
– at a slow gait	69 (85%)	43	3	8	15
– at a fast gait	52 (64%)	28	4	10	10
Lameness after strenuous activity	19 (23%)	13	-	5	1
Lameness during wet or cold weather	20 (24%)	16	1	3	-
Satisfactory outcome	78 (96%)	48	4	11	15

BW = Body weight

**Table 3** Functional outcome in relation to body weight.

		Functional Outcome		
		Good	Satisfactory	Unsatisfactory
Dogs	<15 kg BW	16	7	28
	15 - 25 kg BW	3	1	-
	>25 kg BW	2	3	6
Cats	4.4 kg BW (mean)	10	5	-

BW = Body weight

undergone resection of the lesser trochanter (► Table 5). The proportion of functionally unsatisfactory results was slightly larger after incomplete resection than after complete resection. Radiographs taken at follow-up evaluation showed bony proliferation in the area of the lesser trochanter in 34 patients (51%); 13 of those patients had the lesser trochanter resected and 21 did not (► Fig. 5). Ossifications in this region were consistently seen in all cats (► Fig. 6), whereas in dogs the frequency of osteophyte formation was similar after complete or incomplete resection of the femoral head and neck. There was no correlation between osteophyte formation and functional outcome.

On average, gait analysis of all dogs that were assessed using kinetic data showed a shortened stance time in the operated limb compared with the contralateral limb (► Table 6). In dogs that weighed less than 15 kg, the peak vertical ground reaction force was minimally increased at a walk and in-

creased by up to 13% of body weight at a trot, whereas in dogs that weighed more than 25 kg, the operated leg was loaded a mean of six percent of body weight less at both gaits. However, only one large dog was assessed at a trot on the treadmill. As a measure of the speed of force transfer, the slope of the ground reaction curve was steeper in small dogs compared with large dogs. The integral (total area under the curve), which measures the loading impulse, was increased only at a trot and decreased for the remaining gaits because of the shortened stance time (► Fig. 7). Kinematic amplitudes of the hip, stifle, and tarsal joints varied considerably, but graphs showed a characteristic pattern for each joint. The coxofemoral angle was mildly decreased in small dogs and markedly decreased in large dogs indicating a reluctance to extend the joint (► Fig. 8). Compensation for the decreased coxofemoral angle was achieved mainly via extension of the tarsal joint.

**Table 2**

Subjective information obtained from owners of 66 dogs and 15 cats after femoral head and neck ostectomy.

**Table 4** Functional outcome in relation to duration of preoperative clinical signs.

Results	Mean duration of preoperative signs (weeks)
Good	5
Satisfactory	7
Unsatisfactory	7

## Discussion

In veterinary medicine, the pioneers of FHO (21, 24) were pleased to have found a promising, simple and inexpensive method for treatment of difficult hip problems. However, the use of FHO as a panacea must be viewed very critically. In our study, the efficacy of FHO was investigated in a population limited to dogs and cats with predominantly chronic (weeks) preoperative signs (14, 16). Our results were in agreement with those of Duff and Campbell, who found that progressive muscle atrophy and contracture associated with lameness had an adverse effect on the surgical outcome (4). In contrast to total hip replacement complete rehabilitation of the musculature generally does not occur after FHO (9, 15).

The age of the patients had no correlation with outcome, which was in agree-

**Table 5** Radiographic findings and functional results of 55 dogs and 12 cats immediately after femoral head and neck ostectomy and a mean of four years postoperatively.

Radiographic findings	Functional results: Dogs (n = 55)				Functional results: Cats (n = 12)			
	Total	Good	Satisfactory	Unsatisfactory	Total	Good	Satisfactory	Unsatisfactory
<b>Immediately postoperative</b>								
• Incomplete resection	15				6			
• Complete resection	40				6			
– With removal of lesser trochanter	19				3			
– Without removal of lesser trochanter	21				3			
<b>Follow-up examination*</b>								
Bony proliferations	34	10	7	17	12	7	5	-
• with incomplete resection	9	2	1	6	6	3	3	-
• with complete resection	25	8	6	11	6	4	2	-
– With removal of lesser trochanter	13	4	5	4	3	2	1	-
– Without removal of lesser trochanter	12	4	1	7	3	2	1	-
No bony proliferations	21	7	2	12				
• with incomplete resection	6	3	-	3				
• with complete resection	15	4	2	9				
– With removal of lesser trochanter	6	-	1	5				
– Without removal of lesser trochanter	9	4	1	4				

\*Follow-up examinations were done a mean of four years after femoral head and neck ostectomy.

ment with the results of Gendreau and Cawley (6). It was impossible to determine retrospectively the effect of modifications of the surgical technique, such as the interposition of the joint capsule or fixation of the greater trochanter with sutures, on the outcome, because of incomplete medical records. Evaluation of the radiographs showed that removal of the lesser trochanter to eliminate pain associated with contact between the femur and pelvis had no effect on the outcome; bony proliferations that developed at the site of the resected or intact lesser trochanter did not correlate with the functional result. The rate of unsatisfactory results after incomplete resection of the femoral neck was slightly higher than after complete resection, which corresponded to the findings of Lee and Fry (10).

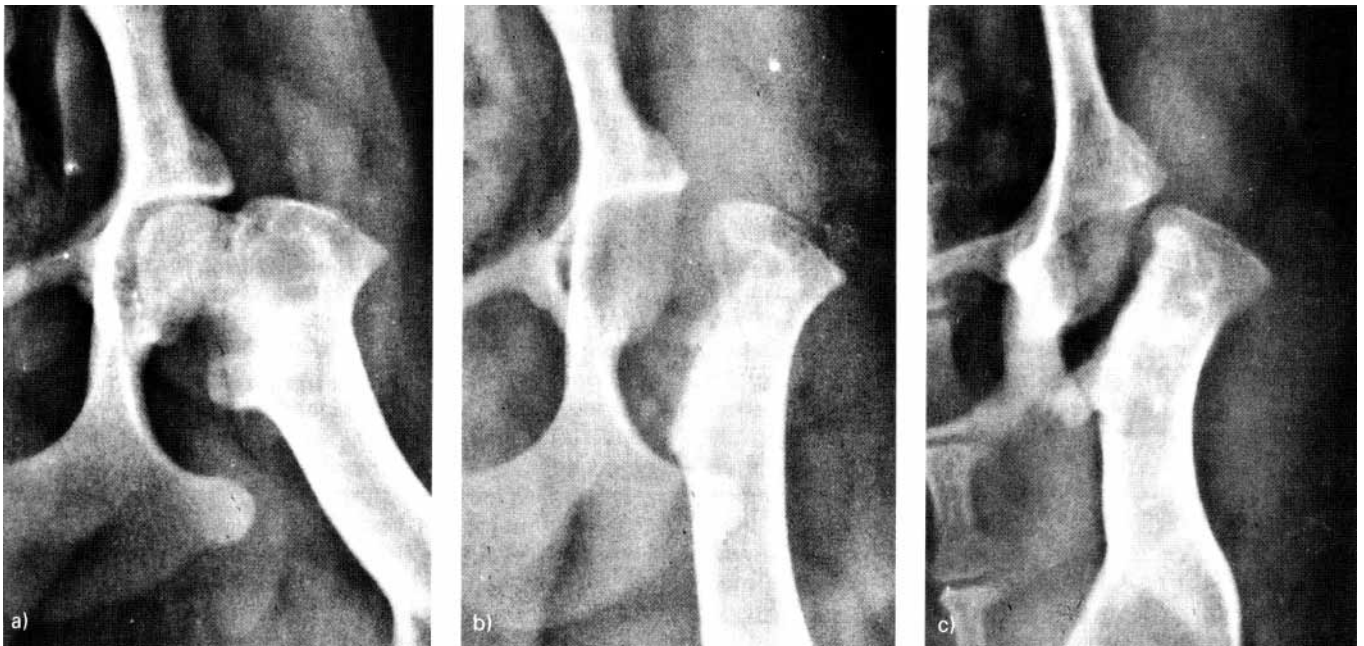
However, there was little correlation between clinical and radiographic findings, similar to the results of Duff and Campbell (5).

Of the 81 dogs and cats, limb function was rated good in 38%, satisfactory in 20%, and unsatisfactory in 42% at a mean of four years postoperatively. These results may appear poor compared with other studies, but one must consider that the majority of those studies were based on evaluations by the owners (1, 2, 4, 7, 8, 10–12, 20–22, 24). The overwhelming majority (96%) of owners of our patients also reported favourable results.

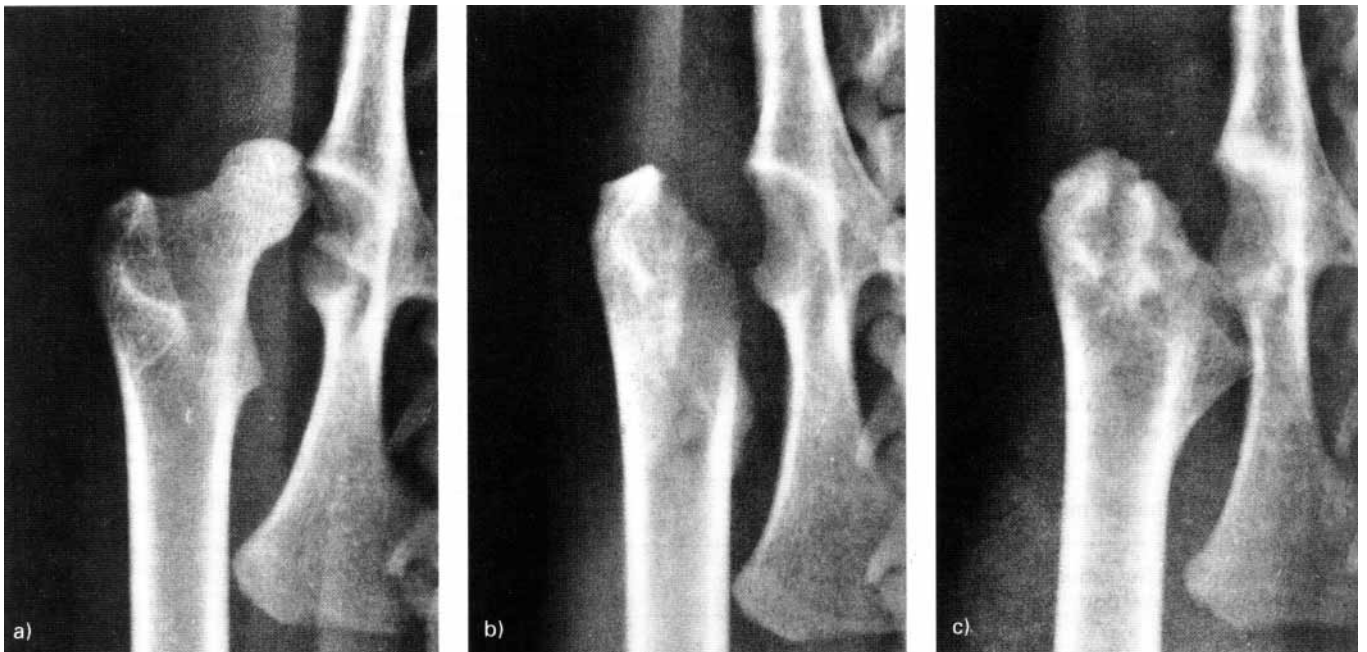Despite non-weight-bearing lameness, some dogs had no pain or a restricted range-of-motion that could account for the lameness. Passive movement of the operated limb

elicited pain in only about 33% of patients, whereas lameness occurred in 56% of cases, and other indicators of malfunction, such as muscle atrophy, were detected in a larger number of animals (► Table 1). Hence, the cause of lameness is not always apparent. In the absence of pain, lameness may be mechanically induced by scar tissue formation. The results of gait analysis revealed functional impairment in all 17 dogs after FHO. They had a reduced ground contact time regardless of body weight, even those patients in which lameness was not detected visually during the clinical examination. In small dogs, the vertical ground reaction force at a walk was almost equal in both hindlimbs, whereas in the (relatively small number of) large dogs, this force was decreased in the operated limb, presumably in an attempt to





**Fig. 5** Radiographs of an eight-month-old, 5 kg, Jack Russell Terrier with Legg-Calvé-Perthes disease. Ventrodorsal view of the pelvis: **a)** Preoperatively; **b)** immediately after surgery with complete resection including the lesser trochanter; **c)** eight months postoperatively with mild bony proliferations without functional impairment.



**Fig. 6** Radiographs of a two-year-old, 3.5 kg, cat with coxofemoral relaxation. Ventrodorsal view of the pelvis: **a)** Preoperatively; **b)** immediately after surgery with incomplete resection of the lesser trochanter; and **c)** 2 years and 8 months postoperatively. There is marked bony proliferation at the lesser trochanter without functional impairment.

spare the limb. With the exception of one dog, kinetic studies could be carried out only in small dogs at a trot; the results showed that there was an increased load on the operated limb. This phenomenon was noted by Dueland et al in a comparative study of total hip replacement and FHO, which prompted the authors to initially doubt the superiority of joint replacement over FHO in quadrupeds (3). However, we know now from gait analysis in humans with limb shortening that the increased load is caused by a shift of the centre of gravity toward the shortened side (13).

In our study, owners often noted that their dogs avoided trotting. At a trot, diagonal pairs of limbs move forward together and one pelvic limb briefly carries approximately 60–80% of the body weight. It is not known whether avoidance of trotting was related to the occurrence of this short-term high load or whether it was attributable to a reduction in hip extension. Based on our kinematic data, dogs with decreased hip amplitudes after FHO compensate mainly by increasing extension of the tarsal joint.

In conclusion, the present study revealed discrepancies between the results of objective clinical data and subjective observations by owners with regard to FHO; this clearly indicated that the efficacy of a surgical treat-

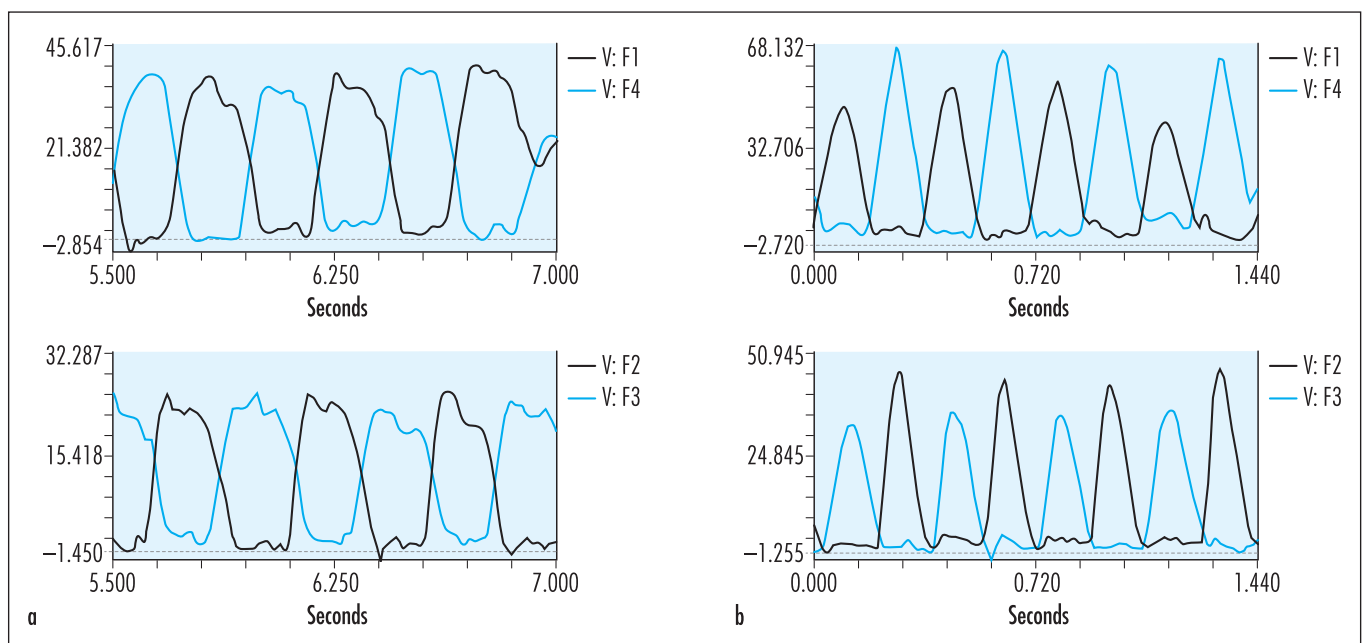
**Table 6** Results of gait analysis in 17 dogs after femoral head and neck ostectomy.

Mean values	Dogs <15 kg BW (3.7 - 13.1 kg) n = 14		Dogs >25 kg BW (28.1 - 44.5) n = 3	
	Operated / contralateral limb		Operated / contralateral limb	
Stance time (msec)	Walk	360 / 376	Walk	563 / 626
	Trot	216 / 226	Trot	250 / 270
Peak vertical ground reaction force (% BW)	Walk	48 / 47	Walk	39 / 45
	Trot	77 / 64	Trot	67 / 72
Slope of ground reaction force (% BW/sec)	Walk	4.41 / 3.83	Walk	1.44 / 2.57
	Trot	9.32 / 7.44	Trot	5.60 / 7.80
Impulse (% BW x sec)	Walk	0.111 / 0.113	Walk	0.16 / 0.20
	Trot	0.074 / 0.068	Trot	0.10 / 0.11
Amplitude of hip joint angle (degrees)	Walk	17 / 18	Walk	20 / 36
Amplitude of stifle joint angle (degrees)	Walk	33 / 29	Walk	35 / 35
Amplitude of tarsal joint angle (degrees)	Walk	34 / 25	Walk	40 / 36

BW = Body weight

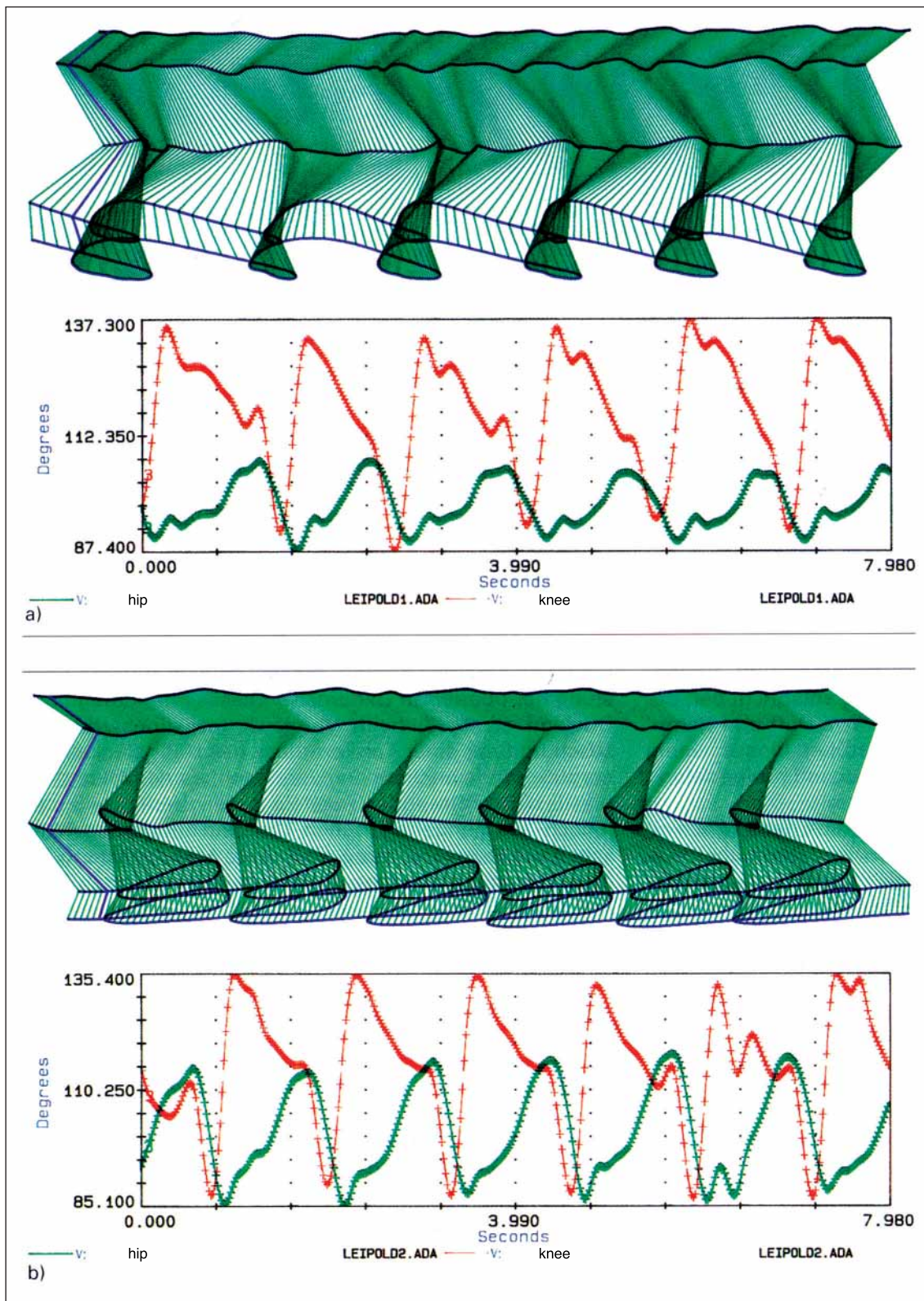
ment should not be determined by a questionnaire. The current assumption that small dogs compensate better after FHO than large dogs must be revised in light of our gait analysis results. The pain reduction

afforded by FHO occurs at the cost of some loss of limb function even in small dogs, in which lameness may be difficult to detect with the naked eye because of their rapid motion. Therefore, FHO should be re-



**Fig. 7** Ground reaction curve, 5.8 kg Yorkshire Terrier six years after right femoral head and neck ostectomy at a) a walk, and b) a trot. Y-axis: N = Newton; X-axis: Time in seconds; F1 = Right forelimb; F4 = Left forelimb; F2 = Right hindlimb; F3 = Left hindlimb.





**Fig. 8** Schematic representation of angles of hip and stifle joints of a 44.5 kg, St. Bernard 6 years and 7 months after right femoral head and neck ostectomy; a) right hindlimb, b) left hindlimb. Green: angle of hip joint; red: angle of stifle joint; y-axis: angle (degrees); x-axis: time (sec).



stricted to exceptional circumstances, where joint preservation is not possible or when infection or other contra-indications preclude joint replacement, even in small dogs (16).

## References

- Berzon JL, Howard PE, Covell SJ, et al. A retrospective study of the efficacy of femoral head and neck excisions in 94 dogs and cats. *Vet Surg* 1980; 9: 88–92.
- Bonneau NH, Breton L. Excision arthroplasty of the femoral head. *Canine Pract* 1981; 8, 2: 13–25.
- Dueland R, Bartel DL, Antonson E. Force-plate technique for canine gait analysis of total hip and excision arthroplasty. *J Am Anim Hosp Assoc* 1977; 13, 5: 547–552.
- Duff R, Campbell JR. Long term results of excision arthroplasty of the canine hip. *Vet Rec* 1977; 101: 181–184.
- Duff R, Campbell JR. Radiographic appearance and clinical progress after excision arthroplasty of the canine hip. *J Small Anim Pract* 1978; 19, 8: 439–449.
- Gendreau C, Cawley AJ. Excision of the femoral head and neck: The long-term results of 35 operations. *J Am Anim Hosp Assoc* 1977; 13, 5: 605–608.
- Hofmeyr CFB. Excision arthroplasty for canine hip lesions. *Mod Vet Pract* 1966; 47, 2: 56–58.
- Junggren GL. A comparative study of conservative and surgical treatment of Legg-Perthes' disease in the dog. *Anim Hosp* 1966; 2: 6–10.
- Kosfeld HU. Der totale Hüftgelenkersatz beim Hund. Klinische, röntgenologische und ganganalytische Erhebungen in den Jahren 1983 bis 1993. Diss med vet, München 1996.
- Lee R, Fry PD. Some observations on the occurrence of Legg-Calvé-Perthes' disease (Coxaplasia) in the dog, and an evaluation of excision arthroplasty as a method of treatment. *J Small Anim Pract* 1969; 5: 309–317.
- Lippincott CL. Excision arthroplasty of the femoral head and neck utilizing a biceps femoris muscle sling. Part Two: The caudal pass. *J Am Anim Hosp Assoc* 1984; 20: 377–384.
- Lippincott CL. A summary of 300 surgical cases performed over an 8 year period: excision arthroplasty of the femoral head and neck with a caudal pass of the biceps femoris muscle sling (Scientific Meeting Abstract). *Vet Surg* 1987; 16, 1: 96.
- Lüttschwager P. Zum Einfluß statischer und muskulärer Dysbalancen auf die Bewegungsasymmetrie beim Laufen mit unterschiedlichen Geschwindigkeiten. Dipl.-Arbeit 1992, Sporthochschule Köln.
- Matis U, Waibl H. Proximale Femurfrakturen bei Katze und Hund. *Tierärztl Prax* 1985; Suppl.1: 159–178.
- Matis U, Knobloch S, Off W. Der Hüftgelenkersatz beim Hund. 9 Jahre Erfahrung an der Chirurgischen Tierklinik der Ludwig-Maximilians-Universität München. 1. Seminar des AMC New York, Tegernsee, 1992 (Abstract).
- Matis U. Operationsverfahren bei Hüftgelenkdysplasie. *Tierärztl Prax* 1995; 23: 426–431.
- Matis U, Schebitz H, Waibl H. Zugang zum Hüftgelenk von kranio-lateral. In: Operationen an Hund und Katze, 2. Aufl. Schebitz H, Brass W (Hrsg.) Berlin: Blackwell.
- Off W. Klinische und ganganalytische Erhebungen zur Resektionsarthroplastik des Hüftgelenks bei Hund und Katze in den Jahren 1978 bis 1989. Diss med vet München 1993.
- Off W, Matis U. Ganganalyse beim Hund. Teil 2: Aufbau eines Ganglabors und bewegungsanalytische Untersuchungen. *Tierärztl Prax* 1997; 25: 303–311.
- Olsson SE, Figarola F, Suzuki K. Femoral head excision arthroplasty. *Clin Orthop Rel Res* 1969; 62: 104–112.
- Ormrod AN. Treatment of hip lamenesses in the dog by excision of the femoral head. *Vet Rec* 1961; 73: 576–577.
- Piermattei DL. Femoral head ostectomy in the dog: Indications, technique and results in ten cases. *Anim Hosp* 1965; 1: 180–188.
- Seer G, Hurov L. Simultaneous bilateral coxofemoral excision arthroplasty in the dog. *Can Vet J* 1968; 9: 70–73.
- Spreull JSA. Excision arthroplasty as a method of treatment of hip joint diseases in the dog. *Vet Rec* 1961; 73: 573–576.